

DSC EXAMINATION OF THE ESOPHAGUS AFTER IMPLANTATION OF SPECIAL STENTS, DESIGNED FOR THE MANAGEMENT OF ACUTE ESOPHAGUS VARICEAL BLEEDING

Experimental study

L. Benkó¹, J. Danis², R. Hubmann², G. Kasza³, Éva Gömöri⁴, Erzsébet Róth¹ and D. Lőrinczy^{5*}

¹Department of Surgical Research and Techniques, Faculty of Medicine, University of Pécs, 7624 Pécs, Kodály Z. str. 20, Hungary

²L. Boltzmann Institute for Laparoscopic Surgery, Department of Surgery II., Hospital Linz, 4020 Linz, Krankenhaus str. 9, Austria

³Department of General and Vascular Surgery, Faculty of Medicine, University of Pécs, 7624 Pécs, Rákóczi str. 2, Hungary

⁴Institute of Pathology, Faculty of Medicine, University of Pécs, 7624 Pécs, Szigeti str. 12, Hungary

⁵Institute of Biophysics, Faculty of Medicine, University of Pécs, 7624 Pécs, Szigeti str. 12, Hungary

Massive bleeding from esophagus varices presents a life threatening complication of portal hypertension. No effective method of treatment is available until now, that would guarantee high grade of patient wellness during the conditioning and investigation phase until the definitive treatment could be introduced. The aim of this study was to evaluate the tissue response to esophagus stents – designed for manage acute variceal bleeding – in animal experiment.

Self-expandable nitinol stents were introduced into the esophagus of six porcines. Another twelve porcines were undergone the same procedure, using the new biodegradable stents made of PDO (polydioxanon). Histological investigations of the stented esophagus segments were observed after 2 and 4 weeks at the first 12 animals. To monitor the time of stent degradation, histology were performed 7 and 12 weeks after the implantation in the biodegradable group (3–3 animals). Differential scanning calorimetric examination was performed in all esophagus samples.

Focal erosion of the esophagus segments was more explicit in the nitinol group at the histology. On the 7th week all of the biodegradable stent were in the stomach and on the 12th week these were completely solved. DSC examination showed significant alterations in the structure of the esophagus in both stented group compared to the healthy control.

This experiment showed that the new self-expandable stents are safety and suitable procedure without deterioration of the esophageal wall. According to our DSC results the thermal denaturation of intact esophagus, its mucosa and muscle fragments revealed significant differences compared to healthy sample in favour the new biodegradable stent. Safety and efficiency in the experimental model had encouraged us to apply this method successfully patients with bleeding esophagus varices. The long term goal is to show that stent placement could be an effective way of decreasing or stabilising the acute bleeding from ruptured esophagus varices in cirrhotic patients.

Keywords: biodegradable, DSC, esophagus variceal bleeding, portal hypertension, SEMS

Introduction

Acute esophagus variceal bleeding presents a life threatening complication of portal hypertension. A patient's first variceal haemorrhage is associated with mortality up to 50% in 6 weeks. Incidence of recurrent bleeding ranges between 30–40% within the subsequent 6 weeks, and 70% of the patients die within the first year [1, 2]. The standard treatment consists of stabilizing the patients and administering antibiotic prophylaxis; vasoactive therapy should be started as soon as possible before endoscopic treatment. Endoscopic therapy has become the gold standard in the management of acute variceal hemorrhage. This form of treatment stops the bleeding in approximately 80% of cases. In situations when the

bleeding cannot be stopped despite combination of endoscopic and drug therapy, especially in patients after several procedures of sclerotherapy leading to sclerosis of the mucosa [3]. Balloon tamponade is widely available and easy to apply in emergency situations, however it also has several disadvantages and furthermore this method can cause the pressure necrosis of the oesophagus, after 48–72 h.

Consequently, no effective method of treatment is available until now, which would guarantee high grade of patient wellness during the conditioning and investigation phase until the definitive treatment could be introduced. Therefore we searched an alternative method to compress the bleeding varices. The placement of self-expanding metal stents for palliation of malignant esophagus strictures and eso-

* Author for correspondence: denes.lorinczy@aok.pte.hu

phago-tracheal fistulas are effective and safe [4, 5]. The fact that we have not found any report in the literature about SEMS application in acute variceal bleeding had encouraged us to use stents usually used for esophageal malignancy in an emergency situation of variceal bleeding instead of balloon tampon at the emergency ambulance and furthermore develop a special stent for this individual indication. In our previous study we have already proved the feasibility of the new self-expandable SX-ELLA-Danis stent in animal experiment and in clinical practice [6, 7]. However, the usefulness of metallic stents for variceal bleeding is limited due to relatively little information regarding their complications, including migration, the formation of strictures or fistulas, and hyperplastic tissue reactions. And also the removal procedure with gastroscopy could injure the crusted wall of the esophagus. It is highly desirable to develop a stent that could be kept in the proper position during the repair process, and then be easily removed, thus avoiding recurrent bleeding. In other words, if a stent could be constructed from a biodegradable material, then a subsequent stent removal operation would not be necessary. Recently, we developed with the Ella-CS Company (Hradec Kralove, Czech Republic) a new biodegradable stent by polydioxanone (PDO) meshed stent for the treatment of patients with bleeding varices.

Aim of the study

In this study we proved the feasibility of the new biodegradable stent designed for stop acute variceal bleeding. Furthermore we compared the destructive effect of the two stents to the normal esophageal wall. And last we monitored the time of stent degradation. The local pressure of the stents may result a decrease in the local microcirculation resulting in tissue damage. We aimed to demonstrate possible deformations of the tissue elements building up the esophagus after the implantation of these two special stents.

Experimental

Materials and methods

Design of the stents and the delivery system

Each stent with the introducer sets were especially designed to be an effective method in the treatment of the acute phase of esophageal varix bleeding until the definitive therapy could be introduced. Both stents have a special delivery system with active length of 60 cm, and body diameter of 22 French, and with an inflatable balloon, that allows a placement without radioscscopy or even endoscopic control.




Fig. 1 The new biodegradable stent

The new biodegradable stent (ELLA-CS Company, Hradec Kralove, Czech Republic) is formed from one piece of the single absorbable PDO monofilamentous fiber (diameter 30 μ m, length 105 mm). The edges of the stent ends are ended with non traumatic bends not to injure the esophagus (Fig. 1). The stent is equipped with radiopaque markers on the ends and the middle of its body. The structure of the polydioxanone monofilamentous fiber turns disrupted and gradually degrades after 4–5 weeks. The final products of degradation are water and carbon dioxide. The degradation results in disintegration of the biodegradable stent and its degraded parts leave the patient's body in a natural way.

The other self-expandable metal stent SX-ELLA-Danis[®] (ELLA-CS Company, Hradec Kralove, Czech Republic) is a nitinol (nickel–titanium) monofilament woven wire mesh stent with flared ends preventing of the migration, and a polyurethane inner coating layer that leaves 1 cm of exposed wire at each ends. The stent has a length of 105 mm, a body diameter of 21 mm, and a diameter of flare ends of 28 mm. The midstent (body of the stent) and the two ends have Pt/Ir radiopaque markers, to keep visible on the X-ray examination after the successful implantation or in fortuitous case of migration. Movable stainless steel wires with Au marker were placed on the two ends ensuring the possibility of position correcting or make easier removing after the management.

Animal preparation and anaesthesia

All experiments were in accordance to rules and regulations regarding the use of animals in medical research. The present study was approved by the local institutional committee on animal research of Péc University (BA 02/2000-29/2001).

Eighteen landrace pigs, mean mass were 31.95 kg, range 28 to 35 kg, were used in the study. After premedication with an intramuscular injection of Azaperon (Stresnil 0.4 mg kg⁻¹, Janssen Cilag-Pharma, Vienna, Austria), short anaesthesia was induced with i.v. Thiopental-sodium injection.

Lidocain spray was sprinkled into the pharynx before the procedure in all animals.

Stent introduction

The experiment was carried out in two groups. In the first group the new biodegradable self-expandable stents were introduced into the distal esophagus of twelve porcines. After the correct positioning of the stent with an inflated balloon at the distal end of the introduction set, the stent was released. Delivery system was removed after the procedure. In the second group six porcines were undergone the same procedure, using the SX-ELLA-Danis stent. After the successful stenting the correct position of the stents was identified with gastroscope and X-ray examination in both groups. A watery consumption food diet was administered from the first postoperative day to reduce the risk of early stent migration. Histological investigations of the stented esophagus segments were observed after 2 and 4 weeks at the first 12 (6–6) animals. To monitor the time of stent degradation, histology were performed 7 and 12 weeks after the implantation in the biodegradable group (3–3 animals). The esophagus samples were inspected for mucosal injury due to the local pressure of the stent, and the possible necrosis of the esophagus wall. Differential scanning calorimetric examination (DSC), which is a well-established method for the demonstration of thermal consequences of local and global conformational changes in biological systems, was performed in all esophagus samples.

Sample preparation

After the follow up periods the 15 cm long segment of the esophagus with the stent and the control normal wall above the involved area were removed, and carefully purified from tissue fragments. Esophagus samples were derived into mucosal and muscle tissue layer, to investigate separately the differences between the distinct tissue constituents and the whole wall.

All the esophagus samples weighted identically ca. 100 mg, that represents a 5 mm long, 5 mm wide segment with a height of 3 mm. Samples were washed 3 times in PBS (Sterile Phosphate-buffered saline, pH 7.4) in order to eliminate all tissue remnants. Samples were treated with DMEM-F12 solution (GIBCO lab) containing 10% (FBS) foetal bovine serum (HYCLONE lab), antibiotic, antimycotic solution (1 U mL⁻¹ penicillin, streptomycin, gentamycine and fungisone, GIBCO), non-essential amino acids (GIBCO), and sodium carbonate. All the individual samples were stored separately at 4°C, no longer than 24 h. Then samples were subjected to calorimetric measurement.

DSC measurements

The thermal unfolding of the healthy and stented esophagus preparations were monitored by Setaram Micro DSC-II calorimeter. All experiments were conducted between 5 and 80°C. The heating rate was 0.3 K min⁻¹ in all cases. Conventional Hastelloy batch vessels were used during the denaturation experiments with 850 µL sample volume (esophagus samples plus buffer) in average. Typical sample wet masses for calorimetric experiments were between 200–250 mg. DMEM-F12 (with admixtures) buffer was used as a reference sample. The sample and reference vessels were equilibrated with a precision of ±0.1 mg. There was no need to do any correction from the point of view of heat capacity between sample and reference vessels. The repeated scan of denatured sample was used as baseline reference, which was subtracted from the original DSC curve. Calorimetric enthalpy was calculated from the area under the heat absorption curve by using two-point setting Setaram peak integration.

Results and discussion

The stents could be easily implanted with the special introducer in all animals. There were no bleeding or perforation while the introduction of the stents. Correct position of the stents was observed on X-ray examinations after successful implantation in all animals. Stents were well tolerated based on watery food consumption from the second post operation day and normal behaviour in both group.

Two animals from the non degradable group died 10 and 13 days after the implantation due to the necrosis of the esophagus and the following mediastinitis. There was no stent migration in this group. The remained stents have been found in the correct position with visible squeezing injury of the esophageal wall at the autopsy 2 and also 4 weeks after.

2 weeks after the implantation in the biodegradable group all the 3 stents have been found in the correct position, with tissue impression and moderate sign of inflammatory. At the autopsy after 4 weeks in one case stent migration was observed. This caused no perforation or mechanical ileuses and the stent material has begun to dissolve. Seven weeks after the stent implantation all of the stents were in the stomach, and these were almost completely degraded. There were no any sign of the stents in the alimentary tract after 12 weeks.

Histology

Microscopic examination of the stented esophagus was performed in all cases. The esophagus samples

fixed in 4% buffered paraformaldehyde. The blocks were embedded in paraffin and serially sectioned at 5–6 microns and the sections were stained with hematoxylin and eosin (HE).

2–4 weeks after the implantation, microscopic examination of the esophagus in the biodegradable group showed acute and chronic inflammation with gentle fibroblast proliferation limited to the mucosal and the submucosal region of the esophagus wall (Fig. 2). At the histology after 7–12 weeks decreased sign of inflammation was observed. In the nitinol group histology showed mucosal ulceration and transmural inflammation with muscular atrophy where a wire skirt penetrated the esophageal mucosa in all animals after 2 and 4 weeks (Fig. 3). These pigs had no stent related symptoms during the observation period. There were no signs of excessive tissue hyperproliferation inside the stent. In the two cases of perforation serious ulceration and necrosis were observed.

DSC measurements

In Fig. 4 can be seen the thermal denaturation of the different compounds of a healthy esophagus. In case of muscle component at least three, for the mucosa

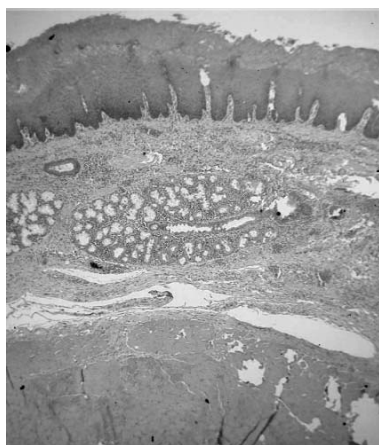

Fig. 2 Focal erosion of the mucosa in the biodegradable group after 2 weeks. HE

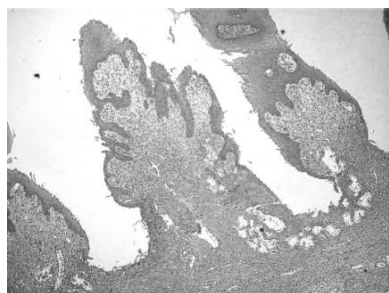


Fig. 3 Mucosal ulceration and transmural inflammation with muscular atrophy where a wire skirt penetrated the esophageal mucosa in the nitinol group after 2 weeks. HE

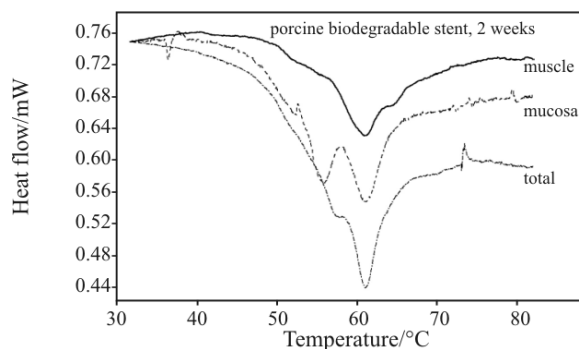


Fig. 4 Thermal denaturation of the esophagus wall (total, mucosa, muscle) in the biodegradable group after 2 weeks

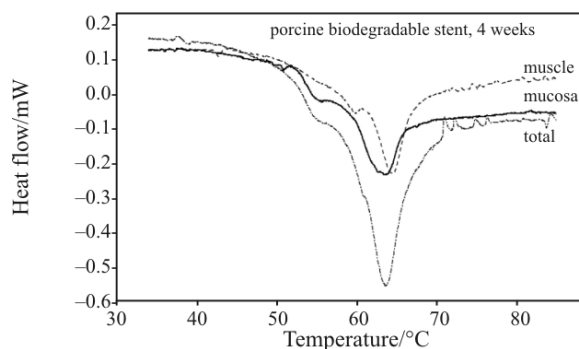


Fig. 5 Thermal denaturation of the esophagus wall (total, mucosa, muscle) in the biodegradable group after 4 weeks

two different thermal domains could be distinguished. The low temperature components of muscle denaturation could be myosin, and the highest ($\sim 62^\circ\text{C}$) is the actin contribution on the basis of measurements performed on rabbit psoas muscles [8, 9]. Applying a biodegradable stent till two weeks, the DSC scans changed significantly (Fig. 5). The mucosa exhibits a new high temperature component, while in case of muscle the contribution of second transition (very probably myosin) manifold increased (Table 1, too). Continuously applied biodegradable stents made further alteration in thermal parameters of muscle compounds (Figs 6, 7, Table 1). The contribution of myosin became less separable, and we can see more

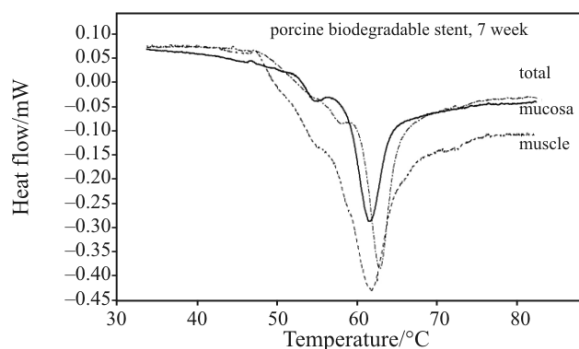


Fig. 6 Thermal denaturation of the esophagus wall (total, mucosa, muscle) in the biodegradable group after 7 weeks

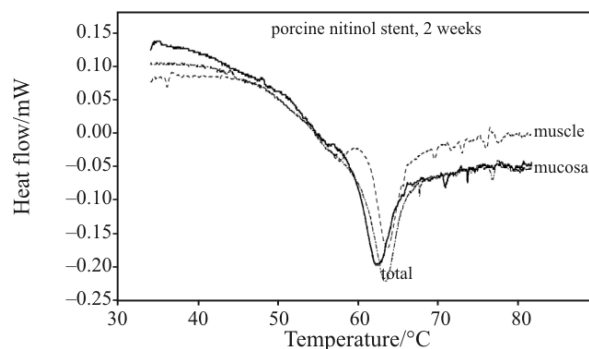


Fig. 7 Thermal denaturation of the esophagus wall (total, mucosa, muscle) in the nitinol group after 2 weeks

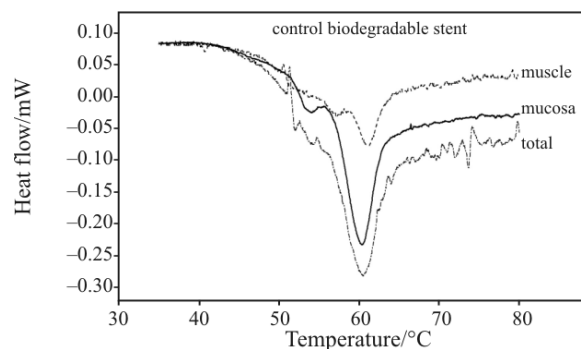


Fig. 9 Thermal denaturation of the healthy esophagus wall (control)

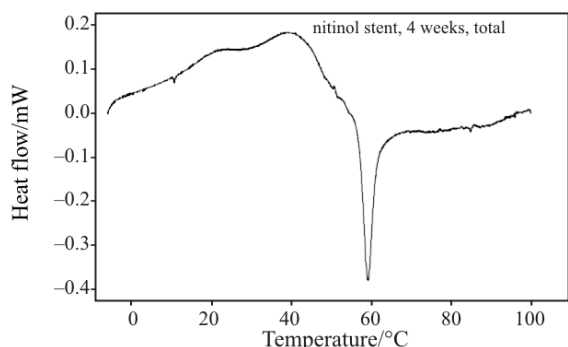


Fig. 8 Thermal denaturation of the esophagus wall in the nitinol group after 4 weeks

pronounced heat capacity change between the native and denatured states with increasing the time of the stent application.

Application of a nitinol stent revealed significant structural alterations compared to the biodegradable one (Fig. 8). The muscle compound after a treatment of two weeks exhibits only two thermal domains, and the heat capacity change between the native and denatured states is greater than in case of biodegradable stent application till seven weeks. This heat capacity change increased in case of treatment for four weeks (Fig. 9).

Massive bleeding from oesophageal varices is the major cause of death in patients with portal hypertension. To decrease the amount of blood loss is very important, and immediate management is required. In the acute phase of bleeding, 20–25% of the patients presenting with variceal haemorrhage continue to bleed, despite the acute drug or endoscopes therapeutic treatment [3]. These patients require further immediate intervention, usually a balloon tamponade. The technique is successful in about 85% of cases, but the risk of recurrent haemorrhage following deflation is up to 50%. The device is uncomfortable for the patient and carries a 14% risk of serious complications, with 5% mortality; include aspiration pneumonia, esophageal rupture and mucosal ulceration. Complications appear to be more common when balloon are placed by inexperienced personnel [2, 10, 11].

Placement of conventional esophageal endoprosthesis and stents for palliation of obstructive esophageal tumor is safe and well established [4, 5]. Surgical implantation of metal cylinder in the case of recurrent esophagus variceal bleeding was first described by Vosschulte in 1957 [12]. In the beginning of the eighties palliative therapy of malignant strictures in the esophagus was revolutionized by the use of SEMS [13]. Nowadays, the stent placement in the

Table 1 Thermal parameters of denaturation of esophagus samples. Data are expressed in mean \pm s.d., the calorimetric enthalpy is normalised to unit sample mass

Time/ week	biodegradable stent						nitinol stent					
	mucosa		muscle		total		mucosa		muscle		total	
	$T_m/$ $^{\circ}\text{C}$	$\Delta H/$ J g^{-1}	$T_m/$ $^{\circ}\text{C}$	$\Delta H/$ J g^{-1}	$T_m/$ $^{\circ}\text{C}$	$\Delta H/$ J g^{-1}	$T_m/$ $^{\circ}\text{C}$	$\Delta H/$ J g^{-1}	$T_m/$ $^{\circ}\text{C}$	$\Delta H/$ J g^{-1}	$T_m/$ $^{\circ}\text{C}$	$\Delta H/$ J g^{-1}
2	56.65	0.397	53.8	0.666	58.7	0.625	56.6	0.527	57.36	0.6	62.5	0.63
	61.25		55.65		61.25		61.8		63			
	64		61.28									
4	54.1	0.84	57.8	0.89	54.45	1.11					58.7	0.944
	61		61.9		61.15						62.2	
7	54.7	0.695	57.5	1.03	55.3	1.324						
	60.7		61.9		60.92							

gastrointestinal tract increases fast, due to the better clinical conditions of the patient after the insertion, and to the easier feasibility of this method. Our aim was to evaluate a new method for decrease or stop the blood loss to stabilize the haemodynamic parameters in the acute phase of varix bleeding as well as to preserve the patient general wellness during the treatment. In our previous work we could demonstrate the efficiency of a new self-expandable metal stent in the management of acute variceal bleeding in animal experiment and also in clinical practice [6, 7]. However this new metallic stent presents less invasive way of treating acute esophagus bleeding, but various complications such as perforation, rebleeding, migration, epithelial in-growth and foreign body reactions could be observed. In cases with serious complications, surgical removal of the metallic stent could be required. Based on this notion, considerable effort should be devoted to avoiding serious complications in patients with acute esophagus variceal bleeding. If the stents gradually degrade while maintaining their dilatation force, they would be ideal treatments for patients with esophagus variceal bleeding. Recently, stents composed of biodegradable materials such as polylactic acids have been developed for treating patients with benign stenosis [14, 15]. The aforementioned biodegradable materials have proven to be biologically safe and have been used in various medical devices such as surgical sutures and bone nails. Experimental and clinical studies have also confirmed that dilation using biodegradable stents is effective for treating various stenotic lesions [14, 15]. The characteristic features of biodegradable stents, their solubility and natural absorption after a certain time period, may prevent the serious complications disagreeable to the use of metallic stents. Furthermore, biodegradable stents are expected to be used as drug delivery systems [16, 17].

This experiment showed mechanical and histological points of view that the new biodegradable stent is a safety and suitable procedure without serious deterioration of the esophageal wall. In this work we could also demonstrate that DSC is a useful and well applicable method for the investigation of the esophagus too, besides other biological/medical applications [18–20]. According to the DSC results, the implantation of the biodegradable stent has improved the thermal stability of the whole esophagus as well as its main components (mucosa and muscle).

Safety and efficiency in the experimental model had encouraged us to apply this method successfully on patients with bleeding esophagus varices. The long term goal is to show that stent placement could be an effective and simple way of decreasing or stabilising

the acute bleeding from ruptured esophagus varices in cirrhotic patients.

Acknowledgements

The Setaram Micro DSC-II was purchased with a grant (CO-272) from the Hungarian Scientific Research Fund (Dénes Lőrinczy).

References

- 1 G. Garcia-Tsao, *Gastroenterology*, 120 (2001) 726.
- 2 D. Sorbi, C. J. Gostout, D. Peura, D. Johnson, F. Lanza, P. G. Foutch, C. D. Schleck and A. R. Zinsmeister, *Am. J. Gastroenterol.*, 98 (2003) 2424.
- 3 H. Okano, K. Shiraki, H. Inoue, T. Kawakita, M. Deguchi, K. Sugimoto, T. Sakai, S. Ohmori, K. Murata and T. Nakano, *Hepatogastroenterology*, 50 (2003) 2013.
- 4 S. H. Lee, *The British J. Radiol.*, 74 (2001) 891.
- 5 A. Dormann, S. Meisner, N. Verin and A. Wenk Lang, *Endoscopy*, 36 (2004) 543.
- 6 R. Hubmann, G. Bodlaj, M. Czompo, L. Benkő, P. Pichler, S. Al-Kathib, P. Kiblböck, A. Shamyieh and G. Biesenbach, *Endoscopy*, 38 (2006) 896.
- 7 L. Benkő, J. Danis, M. Czompo, R. Hubmann, A. Ferencz, G. Jancsó, Z. Szántó, A. Zolyomi, F. Könczöl, Á. Bellyei and E. Róth, *J. Therm. Anal. Cal.*, 83 (2006) 715.
- 8 D. Lőrinczy and J. Belágyi, *J. Therm. Anal. Cal.*, 90 (2007) 611.
- 9 T. Dergez, D. Lőrinczy, F. Könczöl, N. Farkas and J. Belágyi, *BMC Struct. Biol.*, 7 (2007) 41.
- 10 A. S. Wright and L.F. Layton, *J. Gastrointestinal Surgery*, 9 (2005) 992.
- 11 K. Mitchell, D. B. Silk and R. Williams, *Gut*, 21 (1980) 570.
- 12 K. Vosschulte, *Chirurg.*, 4 (1957) 186.
- 13 M. H. Jaffe, D. Fleischer, R. K. Zeman, S. B. Benjamin, P. L. Choyke and L. R. Clark, *Radiology*, 164 (1987) 623.
- 14 J. M. Schakenraad, M. J. Hardonk, J. Feijen, I. Molenaar and P. Nieuwenhuis, *J. Biomed. Mater. Res.*, 24 (1990) 529.
- 15 Y. Saito, K. Minami, M. Kobayashi, Y. Nakao, H. Omiya, H. Imamura, N. Sakaida and A. Okamura, *J. Thorac. Cardiovasc. Surg.*, 123 (2002) 161.
- 16 Y. Saito, K. Minami, H. Kaneda, T. Okada, T. Maniwa, Y. Araki, H. Imamura, H. Yamada, K. Igaki and H. Tamai, *Ann. Thorac. Surg.*, 78 (2004) 1438.
- 17 T. Yamawaki, H. Shimokawa, T. Kozai, K. Miyata, T. Higo, E. Tanaka, K. Egashira, T. Shiraiishi, H. Tamai, K. Igaki and A. Takeshita, *J. Am. Coll. Cardiol.*, 32 (1998) 780.
- 18 G. Sohár, E. Pallagi, P. Szabó-Révész and K. Tóth, *J. Therm. Anal. Cal.*, 89 (2007) 853.
- 19 K. Tóth, G. Sohár, E. Pallagi and P. Révész-Szabó, *Thermochim. Acta*, 464 (2007) 75.
- 20 F. Wilhelm, K. A. Kovács, Z. Vértes and D. Lőrinczy, *J. Therm. Anal. Cal.*, 89 (2007) 863.

DOI: 10.1007/s10973-008-9412-5